

Potential Protective Effects Of Some Dried Fruits Against Oxidative Stress Induced By Monosodium Glutamate (MSG) In Rats

**Ereny Wilson Nagib, *Hala Rashed Ataya*

* Nutrition and food science, Department of Home Economic, Faculty of Specific Education, Ain Shams University, Cairo, Egypt.



مجلة البحوث في مجالات التربية النوعية

معرف البحث الرقمي DOI: 10.21608/jedu.2022.106613.1523

المجلد الثامن العدد 41 . يوليو 2022


الترقيم الدولي

E- ISSN: 2735-3346 P-ISSN: 1687-3424

موقع المجلة عبر بنك المعرفة المصري <https://jedu.journals.ekb.eg/>

موقع المجلة <http://jrfse.minia.edu.eg/Hom>

العنوان: كلية التربية النوعية . جامعة المنيا . جمهورية مصر العربية



Potential Protective Effects Of Some Dried Fruits Against Oxidative Stress Induced By Monosodium Glutamate (MSG) In Rats

**Ereny Wilson Nagib, *Hala Rashed Ataya*

* Nutrition and food science, Department of Home Economic, Faculty of Specific Education, Ain Shams University, Cairo, Egypt.

Abstract

This study was carried out to determine the effect of dried apricot (*Prunus armeniaca L.*) dried fig (*Ficus carica L.*) and dried blueberry (*Vaccinium corymbosum*) against oxidative stress in rats. Fifty- four mature male albino rats weighing 150-160g were divided into two main groups. The first group was the negative group (control-ve) (9) rats, the second group (45) rats was divided into five subgroups, the one was positive subgroup (control+ve) given basal diet BD, the subgroup two fed BD containing (15%) dried apricot, the subgroup three fed BD containing (15%) dried fig, the subgroup four fed BD containing (15%) dried blueberry, the subgroup five fed BD mixture of 15% (dried apricot, fig and blueberry), and all subgroups were given monosodium glutamate (MSG)7% from (BD) by 4.9 g/ kg body weight for rat daily for a month.

The best result recorded by group fed BD containing (15%) combination dried fruits apricot, fig and blueberry in daily feed intake, body weight gain, feed efficiency ratio, and showed improvement in liver enzymes, kidney functions and MDA compared with a all subgroups.

The histopathology results were agreed with the results of serum parameters. These results recommend increasing the consumption of dried fruits apricot, fig and blueberry fruits on reducing the risk of oxidative stress and its damages, and nutrition education programs are needed to illustrate the importance of it in reducing the undesirable effect of monosodium glutamate.

Key words:

Monosodium glutamates, Oxidative Stress, dry apricot, dry fig, and dry blueberry

Introduction:

Monosodium Glutamate (MSG) is one of the food additives most commonly used in commercial products. Its implementation has risen over time and is discovered at every market or grocery store in many distinct ingredients and processed foods. MSG provides a unique aroma to processed foods known in Japanese as umami. This taste sensation is also called "savoury" (Xiong et al., 2009 and Mohammad et al., 2020). MSG is called "China salt" in many nations. It has been correlated with multiple types of toxicity in addition to its flavor- enhancing impacts. MSG was associated with obesity, metabolic disorders, Chinese restaurant syndrome, neurotoxic impacts and reproductive organs damaging impacts. MSG operates on glutamate receptors and releases neurotransmitters that play an important role in both ordinary physiological and pathological procedures. (Abdallah et al., 2014 and Mohammad et al., 2020)

Glutamate receptors have three metabotropic receptor groups (mGluR) and four ionotropic receptor classes (NMDA, AMPA, delta, and kainite). All these kinds of receptors are present throughout the central nervous system. In the hypothalamus, hippocampus and amygdala, they are particularly numerous, where they regulate autonomous and metabolic operations (Zhu and Gouaux, 2017). Results from both animal and human studies have shown toxic impacts on even the smallest dose of MSG. MSG average daily consumption is estimated at 0.3-1.0 g (Solomon et al., 2015), but the toxic dose of MSG in rats is 5–8 g/kg body weight, while the lethal dose is 15–18 g/kg body weight according to (Walker & Lupien, 2000). That neonatal MSG consumption later lays a precedent for obesity growth. Due to MSG consumption, insulin resistance and decreased glucose tolerance in rodents raise concerns about the growth of obesity in humans consuming MSG. The same research found that MSG consumption creates a disruptive energy equilibrium by enhancing the palatability of

food and disturbing the leptin-mediated hypothalamus signaling cascade, which could lead to obesity. (He et al., 2011 and Araujo et al., 2017). MSG has been shown to trigger micro-RNA (mRNA) expression of interleukin-6 (IL-6), tumor necrosis factor-alpha (TNF- α), resistin, and leptin in visceral adipose tissue in a study of the inflammatory profile of MSG induced obesity. This, in turn results in enhanced insulin, resistin and leptin levels in circulation and eventually an impaired glucose tolerance (Roman et al., 2021).

MSG induces a significant reduction in liver transaminases showing hepatic harm. This harm was probably the consequence of long-lasting inflammation connected with non-alcoholic steatohepatitis. It has been reported that MSG has no effect on hunger. However, two hours after ingestion, there are reports of gastric distention triggered by MSG. Changes have also been observed in significant parameters, especially amino acid concentrations. In pig blood samples after MSG consumption, leucine, isoleucine, valine, lysine, cysteine, alanine, tyrosine, and tryptophan were considerably greater than checks. After consumption of food supplemented with MSG, no changes in postprandial glucose and insulin concentrations were noted (Kong et al., 2015 and Geha et al., 2000) A multicenter, double-blind, placebo-controlled, multi-challenge assessment of reported MSG responses was performed. They found that in people who think they respond adversely to MSG, big doses of MSG provided without food could cause more symptoms than a placebo. Nevertheless, there were no persistent or severe impacts of MSG ingestion and the re-testing answers were not compatible. Despite these reports and results, there has been controversy over the impact of MSG on human health (Geha et al., 2000).

The word phytochemical is used to refer to naturally occurring chemical compounds in crops (phyto means plant in Greek), chemicals that may have biological importance but are not identified as essential

nutrients. Scientists estimate the potential for illnesses such as cancer, stroke, or metabolic syndrome to affect as many as 10,000 distinct phytochemicals. For primary metabolism or growth, plants need amino acids, sugars, organic acids, etc. Furthermore, all higher plants produce one or more representatives called secondary metabolites, which are not essential for the metabolism of a plant. (Wink, 2003).

Apricot (*Prunus armeniaca L.*) is categorized as a significant temperate fruit under the *Prunus* species of the Rosaceae family, each and every portion of the fruit is helpful to humanity. The apricot is grown commercially in various areas of the globe. Around 3931 acres of apricot orchards are grown in Egypt, producing 15 724 tonnes of apricot fruits. The pit accounts for 15-16% of the total fruit (Sarhan, 1970; Hallabo et al., 1975). The core, however, accounts for 31% to 38% of the pit (Sarhan, 1970, Hallabo et al., 1975 and Filsoof et al., 1976).

Apricot pits are an apricot processing by-product that remains in large quantities and contains high oil percentages (50%) (Sarhan, 1970). Apricot has a significant role in the nutrition of humans and can be used as fresh, dried or processed fruit.

Fig (*Ficus carica L.*) belongs to the family moraceae. The fig is a southern Arabia native. In India, its business manufacturing in Maharashtra and South India is restricted to a few centers. It is grown commercially in the neighboring fields of Pune and Aurangabad in Maharashtra (Anonymous, 2012).

Fig is an significant component of the Mediterranean diet, regarded an one of the healthiest and linked to longevity. (Calişkan and Polat, 2011). Fig, like proanthocyanidins, is an outstanding source of phenolic compounds. Due to the phenolics they contain, several studies have been carried out on the health-promoting potential of figs (Slatnar et al., 2011). Solomon et al. (2006) The greater the polyphenol content in fig fruit, especially anthocyanins, the greater the antioxidant activity.

Antioxidants from figs can prevent the oxidation of plasma lipoproteins (Vinson et al., 2005). Figs are wealthy in minerals and sugars, mainly fructose and glucose (Vinson, 1999 and Genna et al., 2008).

Blueberry (*Vaccinium corymbosum*) involves a cluster of phenolic acids (e.g., gallic acid, p-hydroxybenzoic acid, chlorogenic, p-coumaric, caffeic, ferulic and ellagic acids) and flavonoids (anthocyanins, catechins, epicatechins, quercetins, kaempferols and myricetins) (Taruscio et al., 2004 and Devareddy et al., 2020) Blueberries contain a range of health-friendly nutrients and associated compounds. They are a very nice source of vitamin C (USDA, 2011). An important quantity of phylloquinone (vitamin K) is provided by blueberries (and a few others such as blackberries, grapes and figs) (Dismore et al., 2003). Blueberries are considered one of the richest foods containing folic acid Honein et al. (2010). Antioxidants are compounds that inhibit oxidation to balance the oxidative stress, and protective from it and improve health in humans (Hatier, and Gould, 2009, Basu et al., 2010).

Therefore, the present study was conducted to study the Potential protective effects of some dried fruits against oxidative stress induced by monosodium glutamate (MSG) in rats.

Materials and Methods

Materials:

Dried Apricot, fig fruit and blueberry were obtained from the local market, Cairo, Egypt.

Albino rats (Sprague- Dawley Strain) weighting (150-160g) were obtained from the national research center Dokki Giza.

Egypt Casein, vitamins, minerals, cellulose, choline chloride and Monosodium glutamate were purchased from El-Gomhorya Company for trading drugs, chemicals and medical instruments. A monosodium

glutamate - containing diet was prepared by adding 7% Monosodium glutamate to the basal diet (BD).

Kits measurement of all parameters for biological experimental were purchased from Bicon Diagnosemittel GmbH and Co. KG Hecke 8 made in Germany.

Methods:

Chemical composition analysis:

Moisture, total protein, total lipid and fiber were analyzed in dry fruit according to AOAC (2010).

Determination of total phenolic compounds:

The samples were obtained using the method Garcia-Salas et al. (2010) outlined and used for spectrophotometric analysis. The total phenolic content of the extracts was determined by a Folin-Ciocalteu phenol reagent method (Xu and Chang , 2007) using gallic acid as standard. The absorbance was measured with UV/vis spectrophotometer (Varian Cary 50 Scan, Australia) at 760 nm. A blank solution was used with a combination of 80 percent methanol and reagents. Through the gallic acid calibration curve, the total phenolic content was expressed as gallic acid equivalents (μg of GAE/ mg dry matter).

Determination of total flavonoids compounds:

The complete content of flavonoids was determined using the technique Heimler et al. (2005). About 250 μl of extract or rutin standard solution or 80% methanol (blank solution) was mixed with 1.25 ml of distilled water and 75 μl of 5% NaNO_2 solution. The mixture was vortexed for 15 sec and standed for 6 min at room temperature. At room temperature, 10% $\text{AlCl}_3 \cdot 6\text{H}_2\text{O}$ (150 μl) was added to the mixture and then incubated for 5 min. The absorbance was immediately evaluated at 510 nm. Total flavonoid content was conveyed through the rutin calibration curve as rutin equivalents (μg RE/ mg dry matter).

Biological investigations:

Fifty four male albino rats were housed in healthy condition (21-23°C) and fed on basal diet for one week before starting the experiment for acclimatization , after this, rats were divided into two main groups, the first group (9 rats) fed on basal diet as a **negative control** (ve-) and the other main group (45 rats) classified into 5 subgroups as follow:

Subgroup(1): Positive control group (ve+), 9 rats and fed on basal diet.

Subgroup(2): 9 rats were fed on deit containing 7% (MSG) and 15% dried apricot.

Subgroup(3): 9 rats were fed on deit containing 7% (MSG) and 15% dried fig.

Subgroup(4): 9 rats were fed on deit containing 7% (MSG) and 15% dried bluberry

Subgroup(5): 9 rats: were fed on deit containing 7% (MSG) and 15% combination dried of apricot, fig and blueberry.

All five subgroups were given monosodium glutamate at a rate of 7% from basal diet by 4.9 g/ kg body weight for rat daily for a month (30 day), while average feed intake for rat (70g/kg) (Mohamed et al., 2018).

At the experimental ending (4 weeks), rats were fasted for 12-h then scarified. According to Drury and Wallington (1980), blood samples were collected from the portal vein into dry clean centrifuge tubes for serum separation, blood samples were centrifuged for 10 minutes at 3000 rpm to separate the serum. In 10 percent formalin solution, the liver of sacrificed rats was held until processed for histopathological examination.

Estimation of Lipid peroxide (Malondialdehyde): lipid peroxide was determined according to the method of Draper and Hadley, (1990).

Liver functions:

Glutamic oxalic transaminase (GOT), Glutamic pyruvic transaminase (GPT) and alkaline phosphatase (ALP) were determined

according to the methods described by Kachmar and Moss, (1976), Varley et al., (1980) and Bergmeyer and Harder (1986) respectively.

Kidney functions

Urea, creatinine and uric acid were determined according to the methods of Patton and Crouch (1977), Henry (1974), and Schultz, (1984) respectively.

Histopathological Examination:

Scarified rat liver washed in slain solution, dried by filter paper, weighed and placed 10 percent in formalin solution for histopathological testing by the technique listed by (Drury and Wallington, 1980).

Statistical Analysis:

ANOVA evaluated the information acquired in this research. For all analyzes, the information implies test was implemented when a substantial difference (pb 0.05) was identified in some variable to assess the difference between the samples. The findings were evaluated using the Windows SAS System software (Seleim and Rashwan, 2008).

Results and Discussion

Chemical Composition of dry apricot, fig and dried Blueberry:

The results presented in Table (1) shows that the carbohydrate, fiber and protein content of dry apricot, fig and blueberry were the highest were 77.98, 7.60 and 4.41% in dry fig powder, meanwhile, blueberry were 76.06, 7.33 and 6.70%, and apricot were 41.54, 6.75 and 3.51% respectively. Whereas, the total lipids and ash content were recorded 2.60, 1.95 and 2.41 in dry apricot, fig and blueberry respectively for lipid also it were 3.56, 2.46 and 3.00% respectively for ash in dry apricot, fig and blueberry, respectively.

Blueberry-derived fruit and products have low lipid content. The value found for fruit in natura (0.73%) was lower than in the USDA

database (U.S. Department of Agriculture, Agricultural Research Service, 2013) (2.09%) and shown by Vasco et al. (2009) (5.26%) for blueberries cultivated in Ecuador. The protein content of the dried blueberries (4.15%) was comparable to that of the fruit (4.10%) and the flour (4.25%). The level of protein in the fruit was greater than that recorded for Andean blueberry (Vasco et al., 2009) it was (3.68%) and similar to that reported in United States Department of Agriculture USDA it was (4.31%). The fruit ash values (1.80%) were greater than those observed in the USDA database it was (1.52%) (USDA, 2013), but lower than those reported by Vasco et al. (2009).

The results of the chemical properties of fig powder indicated that the moisture content of fig powder was 10.43 percent. Hence, due to the less moisture content it is safe for future storage. It was also discovered that fig powder's protein content was 5.26 percent. It was discovered that the fig powder ascorbic acid content was 5.12 mg/100 g. The ascorbic acid content of powder decreased compared to that of fresh fruit owing to ascorbic acid loss during drying owing to nutrient heat sensitivity, Khapre et al. (2015).

Fig fruit is a mixture of unparalleled natural fiber and minerals like iron, potassium, calcium and nutrients. The edible fig, recognized since prehistoric times as a powerhouse of nutrients (Venu et al., 2005).

The resultant in the same table showed that the total phenolic and flavonoids compounds were the highest in the dry fig powder (10.90 and 4.29%) followed by blueberry was 2.75 and 1.31%, apricot was (1.98, 2.97 %) respectively.

This fruit, like most berries, apricot and fig are rich in flavonoids, tannins and phenolic acids. Many studies have shown that apricot, blueberry and fig have several health benefits connected with the presence of such bioactive compounds, in particular anthocyanins (Smith et al., 2000 and Seeram, 2008).

Blueberry is regarded as a "long-life fruit" because of its elevated antioxidant capacity against free radicals and reactive species and is regarded as one of the most important sources of antioxidants in all vegetables and fruits. (Prior et al., 1998). This activity is probably the primary mechanism by which its consumption can reduce the danger of multiple illnesses developing, such as chronic non-communicable diseases (NCDs) caused by oxidative mechanisms. (Halliwell, 2006).

The figs are an important source of vitamins, amino acids, and antioxidants (Solomon et al., 2006). Compounds with antioxidant characteristics such as vitamin C, tocopherols, carotenoids and phenolics can change carcinogens' metabolic activation and detoxification / disposition, influence mechanisms that change tumor cell growth (Kader, 2001).

Some apricot cultivars have lately been assessed for their antioxidant profile, indicating their dietary health-promoting impacts (Leccese et al., 2010). In apricot fruit, antioxidant compounds such as carotenoids, polyphenols and vitamin C were recorded in elevated quantities (Drogoudi et al., 2008; Dragovic-Uzelac et al., 2009; Hegedüs et al., 2011; Sochor et al., 2011; Caliskan et al., 2012; Fan et al., 2018 and Fratianni et al., 2018).

Table (1): Chemical composition of dry fig and dried blueberry (g / 100g)

Fruits nutrients	Dried apricot	Dry fig	Dry blueberry
Moisture	6.50±0.3	5.60±0.51	4.50±0.54
Protein	3.51±0.2	4.41±0.3	6.70±1.02
Total lipid	2.60±0.4	1.95±0.4	2.41±0.2
Total carbohydrates	41.54±2.3	77.98±3.1	76.06±3.9
Fiber	6.75±1.1	7.60±0.9	7.33±0.76
Ash	3.56±0.8	2.46±0.4	3.00±0.33
Total phenolic (µg of GAE/mg)	1.98±0.06	10.90±0.89	2.75±0.2
Total flavonoids (µg of RE/mg)	2.97±0.6	4.29±0.5	1.31±0.04

Body weight gain, total feed intake and feed efficiency ratio of rats

The results in Table (2) showed that the control negative group recorded significant increase in feed intake, body weight gain and feed efficiency group compared to positive control group 14.01 g, 17.86 g/day /each rat and 0.78, respectively. While rats which were fed separately 15 % dried fig, blueberry and mixture fig and blueberry fortified with basal diet showed that significant increasing values compared to the positive group and the formula of (15% mixture from dry apricot, Fig and blueberry) give the best result. Dietary guidelines have recommended increased intakes of fruits and vegetables (Willett et al., 1995). The rationale for such a weight loss hypothesis with enhanced fruit consumption is based on three premises: most fruits give low calories, greater fiber structure and variation of diets high in fruit. In support of this assumption, (Howarth et al., 2001) Specified that soluble or insoluble fiber intake rises after meal satiety under set energy intake and reduces subsequent hunger. Furthermore, high fiber diets reduce energy intake and body weight, at least for short-term follow-up, in the prevention of overweight and obesity (Tetens and Alinia, 2019).

Table (2): Body weight gain , total feed intake and feed efficiency ratio of rats

Groups	Body weight gain (g)	Total feed intake (g/day)	Feed efficiency ratio
Control negative	14.01±3.25 ^{a,b}	17.86±1.03 ^b	0.78±0.02 ^a
Control positive	8.0±1.40 ^d	14.98±1.01 ^c	0.53±0.03 ^b
Apricot 15%	13.33±3.21 ^{a,b}	16.98±0.97 ^b	0.78±0.07 ^{a,b}
Fig 15%	14.33±0.77 ^{a,b}	16.88±0.87 ^b	0.84±0.06 ^{a,b}
Blueberry 15%	14.81±2.97 ^a	15.8±1.01 ^a	0.93±0.82 ^{a,b}
5% apricot,5% fig,5% blueberry	15.62±2.87 ^a	18.91±1.01 ^a	0.82±0.92 ^{a,b}

Each Value represents the mean value ± SD Means in the column with different letters were Significant differences at $p < 0.05$.

Effect of some dried fruits on Malondialdehyde (MDA) and liver enzymes of rats.

Data in Table (3) revealed that the mean value of serum MDA (mg/dl) of rats fed on different diets. It could be noticed that the mean value of MDA of the control (+) group was higher than control (-) group, being $(2.3 \pm 0.017$ & $1.24 \pm 0.25)$ nmol/mL respectively, Rats treated with dried apricot, fig, and blueberry showed lower values in serum level of AST, ALT and ALP as compared to the positive control group. The best treatment was recorded by group (5% apricot+ 5% fig + 5% blueberry) considering serum MDA. This result in the same line with Naziroglu, et al, 2004) they found Apricot also contains vitamins (C, E) and Se (Munzuroglu, et al, 2003) Vitamin E and Se also have antioxidant properties (Ozturk, et al, 2006). Feeding rats for 5 months before exposure to CCl₄ with 10% and 20% apricot-containing improved liver injury caused by CCl₄ and decreased ALT, AST and MDA. (Feral, et al 2009). (Wang et al., 2009 and Wang et al., 2010) showed that blueberries have good protective effects against acute hepatic injury in rats.

Table (3).Effect of some dried fruits on Malondialdehyde (MDA), liver enzymes of rats

Groups	MDA nmol/mL	ALP (U/L)	AST (U/L)	ALT (U/L)
Control negative	$1.24 \pm 0.25^{a,b}$	86.00 ± 1.10^c	67.00 ± 11.10^c	41.32 ± 3.43^c
Control positive	2.3 ± 0.017^a	195.03 ± 1.50^c	111.32 ± 3.11^a	128.42 ± 0.03^b
Apricot 15%	$1.59 \pm 1.21^{a,b}$	103.00 ± 1.14^c	85.67 ± 24.51^b	$61.44 \pm 0.07^{a,b}$
Fig 15%	$1.73 \pm 0.67^{a,b}$	97.00 ± 1.13^c	89.61 ± 31.14^b	$59.46 \pm 0.06^{a,b}$
Blueberry 15%	1.41 ± 0.97^a	96.00 ± 1.12^c	87.01 ± 1.31^a	$57.45 \pm 0.82^{a,b}$
5% apricot, 5% fig, 5% blueberry	1.32 ± 0.77^a	92.00 ± 0.11^c	81.71 ± 51.10^b	$49.47 \pm 0.92^{a,b}$

Each Value represents the mean value \pm SD Means in the column with different letters were Significant differences at $p < 0.05$.

Effect of dry apricot, fig and blueberry on kidney functions of rats.

Results in Table (4) also showed that an increase in the concentration of uric acid, urea and creatinine in the positive group (3.95, 84.98 and 1.22) mg/dl than the negative control group 1.71, 47.31 and 0.67 mg/dl, respectively. Whereas, the rats fed dry apricot, fig, dried blueberry and combination of them significantly reduced. The best result showed group was fed on a mixture of dry apricot, fig and blueberry. These results are in agreement with Khalil and Khedr, (2016) It has been revealed that MSG has enhanced creatinine and urolithiasis concentrations and oxidative stress due to MSG can trigger fibrosis in the kidney induce fibroblast conversion. (Barnes and Gorin ,2011) Found that interstitial tubular fibrosis is strongly associated with renal disease progression. Naser et al. (2015) indicated that rats dried fruit fed (15 percent) enhanced osteoporotic rat kidney function. This research also demonstrates that an apricot diet can decrease oxidative stress, enhance kidney function recovery and stop the death of apoptotic cells (Nigar, et al , 2013).

Table (4) Effect of dry apricot, fig and blueberry on serum kidney functions of rats

Groups	Uric acid (mg/dl)	Urea (mg/dl)	Creatinine (mg/dl)
Control negative	1.71±2.25 ^c	47.86±1.13 ^b	0.67±1.22 ^a
Control positive	3.95±1.30 ^a	84.98±1.21 ^c	1.22±0.13 ^b
Apricot 15%	2.33±3.11 ^{a,b}	66.98±0.77 ^b	0.87±0.37 ^{a, b}
Fig 15%	1.93±0.67 ^{a,b}	61.88±0.87 ^b	0.76±0.06 ^{a, b}
Blueberry 15%	2.00±2.87 ^a	58.01±1.031 ^a	0.75±0.72 ^{a, b}
5% apricot,5% fig,5% blueberry	1.82±2.87 ^a	55.91±1.01 ^a	0.69±0.82 ^{a, b}

Each Value represents the mean value ± SD Means in the column with different letters were Significant differences at $p < 0.05$.

Histopathological examination of liver:

Liver tissues of negative control group revealed normal histological structure (**photo. 1**). While the control positive group (Subgroup2) showed that showing focal area of hepatic necrosis completely replaced by leucocytic cells infiltration (**photo. 2**). On the other hand Subgroup 3 that fed on diet containing "1 5% dried apricot fruit" showed that no showing inflammatory cells infiltration in the hepatic capsule (**photo. 3**). And the liver of rats treated with 1 5% dried blueberry fruit in subgroup 4 showed that dilatation and congestion of central vein (**photo. 4**). Beside liver tissues in subgroup 5 who fed 1 5% dried fig fruit showed few leukocytes in the hepatic sinusoids (**photo. 5**). Moreover the hepatic tissue of rats treated with diet containing "5% dried apricot+5% dried blueberry and 5% dried fig fruit" in subgroup 6 showed that no histopathological changes (**photo. 6**). The histopathological results were agreed and in the same line with the results of serum parameters. This result agree with (Mohamed et al., 2018) who reported that MSG cause focal area of hepatic necrosis.

And agree with (Yilmaz et al., 2013) who showed that apricot help on liver regeneration in rats.

Histopathological Changes of liver:

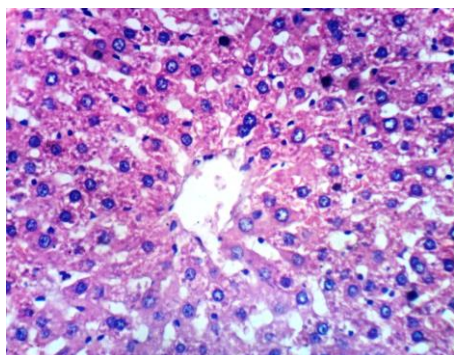


Photo. (1): Liver of control –ve rat showing the normal histological structure of hepatic lobule (Hand E X 200).

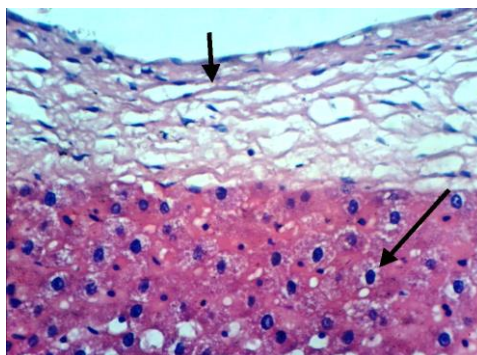


Photo. (2): Liver of control +ve rat showing focal area of hepatic necrosis completely replaced by leucocytic cells infiltration (Hand E X 200).

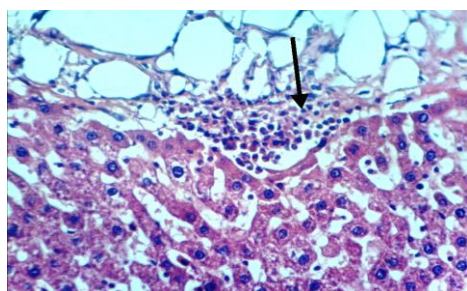


Photo. (3): Liver of rat fed on diet containing "15% dried apricot fruit" showing no showing inflammatory cells infiltration in the hepatic capsule (Hand E X 200).

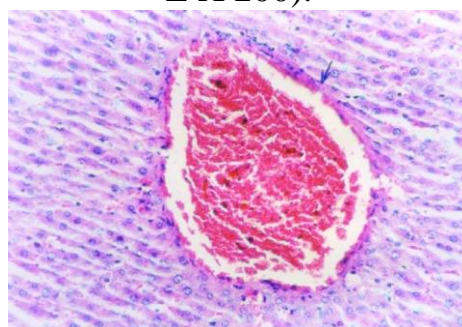


Photo (4): Liver of rat fed on diet containing "15% dried blueberry fruit" showing dilatation and congestion of central vein (Hand E X 200).

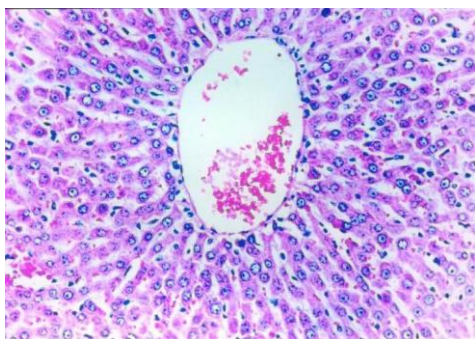


Photo (6): Liver of intoxicated rat fed on diet containing "5% dried apricot+5% dried blueberry and 5% dried fig fruit" showing no histopathological changes (Hand E X 200)

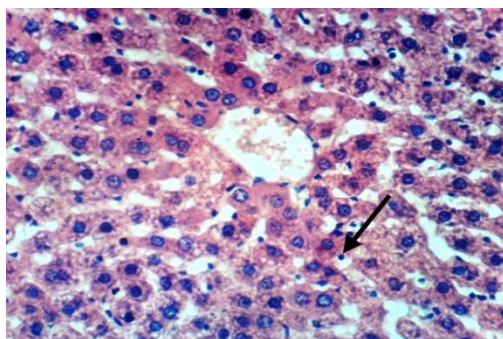


Photo. (5): Liver of rat fed on diet containing "15% dried fig fruit" showing few leukocytes in the hepatic sinusoids (Hand E X 200).

Conclusion and recommendations:

The present study is scientifically proved that dried apricot, fig and dried blueberry fruits intake produced great therapeutic effects against monosodium glutamate (MSG) and improvements serum, liver enzyme activities and kidney function. The best results showed in group fed diet contain (15%) mix of dried apricot, fig and blueberry fruits compare another groups. It could be considered the cheapest nutritious food supplement for sensitive groups. Raising the nutrition awareness with such fruit type for its qualities and biological effects.

References

- 1- Abdallah, C.G.; Jiang , L.; De Feyter, H. M.; Fasula, M.; Krystal, J.H and Rothman, D.L. (2014): Glutamate metabolism in major depressive disorder. *Am J Psychiatry*. 17(11):1320-7.
- 2- Anonymous, A. (2012): Survey of fruits. Directorate of Horticulture, M. S. Pune.
- 3- AOAC (2010): Official Methods of Analysis of Association of Official Chemists. 18th Ed., Washington, D.C., USA.
- 4- Araujo, T. R.; Freitas, I.N.; Vettorazzi, J.F.; Batista, T.M.; Santos , J. C and Bonfleur, M.L. (2017): Benefits of Lalanine or L-arginine supplementation against adiposity and glucose intolerance in monosodium glutamate-induced obesity. *Eur J Nutr*. 56(6):2069-80.
- 5- Barnes, J. L and Gorin, Y. (2011): Myofibroblast differentiation during fibrosis: role of NAD (P)H oxidases. *Kidney Int*. 79(9):944–956.
- 6- Basu, A. M .; Du, M.J.; Leyva, K.; Sanchez, N.M.; Betts, M.; Wu, C.E and Aston T.J. (2010): Blueberries decrease cardiovascular risk factors in obese men and women with metabolic syndrome. *J. Nutr.*, 140(9): 1582-1587.
- 7- Bergmeyer, H and Harder, M. (1986): A colorimetric method of the determination of serum glutamicoxaloacetic and glutamic pyruvic transaminase *Clin. Biochem*. 24: 28-34.
- 8- Caliřkan, O and Polat, A. A. (2011): Phytochemical and antioxidant properties of selected fig (*Ficus carica* L.) accessions from the eastern Mediterranean region of Turkey. *Sci Hort.*, 128(4):473–478.
- 9- Caliskan, O.; Bayazit, S and Sumbul, A. (2012): Fruit quality and phytochemical attributes of some apricot (*Prunus armeniaca* L.) cultivars as affected by genotypes and seasons. *Notulae Botanicae Horti Agrobotanici Cluj-Napoca*. 40(2):284-294.
- 10- Devareddy, L.; Hooshmand, S.; Collins, J.K.; Lucas, E.A.; Chai, S.C. and Arjmandi, B.H. (2020): Blueberry prevents bone

- loss in ovariectomized rat model of postmenopausal osteoporosis. *J Nutr Biochem*. 19(10):694-9.
- 11- Dismore, M.L.; D.B.; Haytowitz, S.E.; Gebhardt, J.W.; Peterson and S.L. (2003): Vitamin K content of nuts and fruits in the US diet. *J. Am. Diet. Assoc.* 103(12): 1650-1652.
- 12- Dragovic-Uzelac, V.; Kovacevic, D.B.; Levaj, B.; Pedisic, S.; Mezak, M.; and Tomljenovic, A. (2009): Polyphenols and antioxidant capacity in fruits and vegetables common in the Croatian diet. *Agriculturae Conspectus Scientificus*. 74(3):175-179.
- 13- Draper, H.H and Hadley, M. (1990): Malondialdehyde determination as index of lipid peroxidation. *Methods in Enzymology*.186:421-431.
- 14- Drogoudi, P.D.; Vemmos, S.; Pantedelis, G.; Petri, E.; Tzoutzoukou, C.; and Karayannis, I. (2008): Physical characters and antioxidant, sugar, and mineral nutrient contents in fruit from 29 apricot (*Prunus armeniaca* L.) cultivars and hybrids. *Journal of Agricultural and Food Chemistry* 5(6):10754-10760.
- 15- Drury, R.A and Wallington, E.A. (1980): *Carlton's Histological Technique*. 5th ed. Oxford University.
- 16- Fan, X.; Xi, Y.; Zhao, H.; Liu, B.; and Jiang, W. (2018): Improving fresh apricot (*Prunus armeniaca* L.) quality and antioxidant capacity by storage at near freezing temperature. *Scientia Horticulturae* 231(27):1-10.
- 17- Feral, O.; Mehmet, G. B.; Burhan ,A.; Cetin, O.; Asli, C.; Nigar, V.; Ali,O and Ismet, Y. (2009): Protective effect of apricot (*Prunus armeniaca* L.) on hepatic steatosis and damage induced by carbon tetrachloride in Wistar rats .*British Journal of Nutrition*. 102(8) 1767–1775.
- 18- Filsoof, M.; Mehran, M and Farrohi, F. (1976): Determination and comparison of oil characteristics in Iranian almond, apricot and peach nuts. *Fette, Seifen, Anstrichmittel*, 78(4), 150-151.

- 19- Fratianni, F.; Ombra, M.N.; Acierno, A.; Cipriano, L.; and Nazzaro, F. (2018): Apricots: biochemistry and functional properties. *Current Opinion in Food Science* 19(2):23-29.
- 20- Garcia-Salas, P.; Morales-Soto, A.; Segura-Carretero, A and Fernández-Gutiérrez, A. (2010): Phenolic compound extraction systems for fruit and vegetable samples. *Molecules*, 15(5):8813-8826.
- 21- Geha, R. S.; Beiser, A.; Ren, C.; Patterson, R.; Greenberger, P. A.; Grammer, L. C.; Ditto, A. M.; Harris, K. E.; Shaughnessy, M. A.; Yarnold, P. R.; Corren, J and Saxon, A. (2000): Review of Alleged Reaction to Monosodium Glutamate and Outcome of a Multicenter Double-Blind Placebo-Controlled Study. *The Journal of Nutrition*. 130(45): 1058S-62S.
- 22- Genna, A.; De Vecchi, P.; Maestrelli, A and Bruno, M. (2008): Quality of 'Dottato' dried figs grown in the Cosenza region, Italy. A sensory and physical-chemical approach. *Acta Hortic*. 798(12):319-323.
- 23- Hallabo, S. A.; El-Wakeil, F. A.; Morsi, M and Khairy, S. (1975): Chemical and physical properties of apricot kernel oil and almond kernel oil. *Journal of Food Sciences*. 3, 1-5.
- 24- Halliwell, B. (2006): Reactive species and antioxidants. Redox biology is a fundamental theme of Aerobic, American society of plant biologists. 11(3):117-97.
- 25- Hatier, J.H and Gould, K.S. (2009): Anthocyanin Function in Vegetative Organs. In: *Anthocyanins: Biosynthesis, Functions, and Applications* (Eds: Gould, K., Davies, K. and Winefield, C.). Spring Science Business Media, LLC, New York, NY. 3(1): 1-19.
- 26- He, K.; Du, S.; Xun, P.; Sharma, S.; Wang, H and Zhai, F. (2011): Consumption of monosodium glutamate in relation to incidence of overweight in Chinese adults: China Health and Nutrition Survey (CHNS). *Am J Clin Nutr*. 93(6):1328-36.
- 27- Hegedüs, A.; Pfeiffer, P.; Papp, N.; Abrankó, L.; Blázovics, A and Pedryc, A. (2011): Accumulation of

- antioxidants in apricot fruit through ripening: characterization of a genotype with enhanced functional properties. *Biological Research* 44(9):339-344.
- 28- Heimler, D.; Vignolini, P.; Dini, M. G and Romani, A. (2005): Rapid tests to assess the antioxidant activity of *Phaseolus vulgaris* L. dry beans. *J Agr Food Chem*, 53:3053-3059.
- 29- Henry, R. (1974): Determination of creatinine by kinetic method. In " *Clinical Chemistry, Principles and techniques* "(2nd edition), Harper& Rowe, 525.
- 30- Honein, M.A.; L.J.; Paulozzi, T.J.; Mathews, J.D.; Erickson and Wong, L.Y. (2010): Impact of folic acid fortification of the US food supply on the occurrence of neural tube defects. *JAMA*, 285(23): 2981-2986.
- 31- Howarth, N.C.; Saltzman, E and Roberts, S.B. (2001): Dietary fiber and weight regulation. *Nutr. Rev.*, 59(5): 129-139.
- 32- Kachmar, J. F and Moss, D. W. (1976): Enzymes, In: *Fundamentals of Clinical*(edited by Tiez N). Philadelphia PA. W.B. Saunders.22(2): 666-672.
- 33- Kader, A. (2001): Importance of fruits, nuts, and vegetables in human nutrition and health. *Perishables Handling Qrtly*. 106:4-6.
- 34- Khalil, R.M and Khedr, N.F. (2016): Curcumin protects against monosodium glutamate neurotoxicity and decreasing NMDA2B and mGluR5 expression in rat hippocampus. *Neurosignals*. 24:81-7.
- 35- Khapre, A.P.; Satwadhar, P.N and Deshpande, H.W. (2015): Studies on standardization of fig fruit (*Ficus carica* L.) powder enriched cookies and its composition. *Asian J. Dairy & Food Res.*, 34 (1) 2015: 71-74
- 36- Kong, X.; Zhou, X.; Feng, Z.; Li, FN.; Ji, Y.J and Tan, B. (2015): Dietary supplementation with monosodium L-glutamate modifies lipid composition and gene expression related to lipid

- metabolism in growing pigs fed a normal-or high-fat diet. *Livest Sci.* 180(8):247-52.
- 37- Larsen, K. (1972): Creatinine colormetric method. *J. of Clin. Chem.*, 41:209.
- 38- Leccese, A.; Bureau, S.; Reich, M.; Renard, C.; Audergon, J.C.; Mennone, C. (2010): Pomological and nutraceutical properties in apricot fruit: Cultivation systems and cold storage fruit management. *Plant Foods Human Nutrition.* 65(6):112-120.
- 39- Mohammad, M. H.; Vahid, S.M.; Reza, Z.A and Abolfazl, S (2020): Natural products as safeguards against monosodium glutamate-induced toxicity, *Iran J Basic Med Sci.* 23(4): 416–430.
- 40- Mohamed, S. E.; Abeer, N. A and Hanem, M. E (2018): Study The Effect Of Some Herps And Seeds As A Protection From The Undesirable Effect Of Monosodiume Glutamate. *Journal of Home Economics*, 28 (4):478-502.
- 41- Munzuroglu, O.; Karatas, F and Geckil, H. (2003): The vitamin and selenium contents of apricot fruit of different varieties cultivated in different geographical regions. *Food Chem.* 83(13): 205–212.
- 42- Naser. B. A.; El-Bahy. A. M.; Abd El-Aziz. A.; Mohamed, H. N and Ibrahem, M. (2015): Effect of Soybean and Some Dried Fruits in Osteoporotic Rats. M.SC. In Education Faculty - Ain Shams University.
- 43- Naziroglu, M.; Karaoglu, A and ksoya, A. O (2004): Selenium and high dose vitamin E administration protects cisplatin-induced oxidative damage to renal, liver and lens tissues in rats. *Toxicology.* 195(15): 221–230.
- 44- Nigar, V.; Hakan, P.; Burhan, A.; Asli, C.; Ali, O. (2013): The protective effects of *Prunus armeniaca L* (apricot) against methotrexate-induced oxidative damage and apoptosis in rat kidney. *J Physiol Biochem.* 69:371–381.

- 45- Ozturk, F.; Ozturk, I.C and Batcioglu, K. (2006): The effect of melatonin on 7,12-dimethyl-benz[a]anthracene injury in comparison with vitamin E þ selenium in mouse kidneys. *Fundam Clin Pharmacol* .20(6): 359–364.
- 46- Patton, C.J and Croush, S.R. (1977): Enzymatic Determination of Urea. *J. Anal. Chem.* 49: 464-469.
- 47- Prior, R. L.; Cao, G.; Martin, A.; Sofic, E.; McEwen, J.; O'Brien, C.; Lischner, N.; Ehlenfeldt, M.; Kalt, W.; Krewer, G and Mainland, C. M. (1998): Antioxidant capacity as influenced by total phenolic and anthocyanin content, maturity, and variety of *Vaccinium* species. *Journal of Agricultural and Food Chemistry*. 46(7), 2686-2693.
- 48- Roman, R.R.; Almanza, J. C.; Garcia, M.R.; Blancas-Flores, G.; Fortis, A and Jasso, E. I. (2021): Monosodium glutamate neonatal intoxication associated with obesity in adult stage is characterized by chronic inflammation and increased mrna expression of peroxisome proliferator-activated receptors in mice. *Basic ClinPharmacolToxicol*. 108(8): 406-13.
- 49- Sarhan, M. A. (1970): Studies on the production of apricot juice. MSc Thesis, Faculty of Agric., Cairo University, Cairo.
- 50- Schultz, A (1984): *Uric Kaplan A. Clin Chem.*, Mosby Co. St. Louis Toronto. Princeton; 1261- and 418.
- 51- Seeram, N. P. (2008): Berry fruits: compositional elements, biochemical activities, and the impact of their intake on human health, performance, and disease. *Journal of Agricultural and Food Chemistry*, 56(3), 627-629.
- 52- Seleim, M. A., Rashwan, M. R. (2008): *SAS System for Windows (Statistical Analysis System), Version 9.2.* Cary, USA: SAS Institute Inc. S.
- 53- Slatnar, A.; Klancar, U.; Stampar, F and Veberic, R. (2011): Effect of drying of figs (*Ficus carica* L.) on the contents of sugars, organic acids, and phenolic compounds. *J Agric Food Chem*. 59(21):11696-702.

- 54- Smith, M. A.; Marley, K. A.; Seigler, D.; Singletary, K. W and Meline, B. (2000): Bioactive properties of wild blueberry fruits. *Journal of Food Science*. 65(2), 352-356.
- 55- Sochor, J.; Skutkova, H.; Babula, P.; Zitka, O.; Cernei, N and Rop, O. (2011): Mathematical evaluation of the amino acid and polyphenol content and antioxidant activities of fruits from different apricot cultivars. *Molecules* 16:7428-7457.
- 56- Solomon, A.; Golubowicz, S.; Yablowicz, Z.; Grossman, S.; Bergman, M.; Gottlieb, H.; Altman, A.; Kerem, Z. and Flaishman, M.A. (2006): Antioxidant activities and anthocyanin content of fresh fruits of common fig (*Ficus carica* L.). *J Agric Food Chem*. 54(11):7717–7723.
- 57- Solomon, U.; Gabriel, O.O.; Henry, E.O.; Adrian, I.O and Anthony, T. E. (2015): Effect of monosodium glutamate on behavioral phenotypes, biomarkers of oxidative stress in brain tissues and liver enzymes in mice. *World J Neurosci*. 5(3):339-49.
- 58- Taruscio, T.G.; Barney, D.L. and Exon, J. (2004): Content and profile of flavanoid and phenolic acid compounds in conjunction with the antioxidant capacity for a variety of northwest *Vaccinium* berries. *J Agric Food Chem*. 52:(3)169–76.
- 59- Tetens, I and Alinia, S. (2019): The role of fruit consumption in the prevention of obesity. *Journal of Horticultural Science & Biotechnology (Special Issue)*: 47-51.
- 60- USDA Department of Agriculture, Agricultural Research Service , (2013): USDA National Nutrient Database for Standard Reference. Release 26. Beltsville: Nutrient Data Laboratory.
- 61- USDA, (2011): National Nutrient Database for Standard Reference, Release 24. Nutrient Data Laboratory.
- 62- Varley, H.; Gewenlock, A and Bell, M. (1980): *Practical Clinical Biochemistry*, Vol.1, 5th ed. London; Williams Heinemen Medical books, Ltd. pp.741:897.
- 63- Vasco, C.; Riihinen, K.; Ruales, J and Kamal-Eldin, A. (2009): Chemical composition and phenolic compound profile of

- mortinone (Vaccinium floribundum Kunth). Journal of Agricultural and Food Chemistry, 57(18), 8274-8281.
- 64- Venu, D.K.; Munjal, S.V.; Waskar, D.P.; Patil, S.R and Kale, A.A. (2005): Biochemical changes during growth and development of Fig (Ficus carica L.) fruits. J. Food Sci. and Technol., 42(3):279-282.
- 65- Vinson, J. A. (1999): The functional food properties of figs. Cereal Foods World, 44(2): 82–87.
- 66- Vinson, J.A.; Zubik, L.; Bose, P.; Samman, N. and Proch, J. (2005): Dried fruits: excellent in vitro and in vivo antioxidants. J Am Coll Nutr., 24(1): 44–50.
- 67- (WHO) World Health Report (2015): The double burden: Emerging epidemics and persistent problems. Geneva, World Health Organization, (document WHO/NUT/97.4).
- 68- Walker R, Lupien JR (2000) The safety evaluation of monosodium glutamate. J Nutr 130:1049S–1052S
- 69- Wang, Y.P.; Cheng, M.L.; Zhang, B.F.; Mu, M.; Zhou, M.Y.; Wu, J.; Li, C.X. (2010): Effect of blueberry on hepatic and immunological functions in mice. Hepatobiliary Pancreat Dis Int 2010; 9: 164-168
- 70- Wang, Y.P.; Zhang, B.F.; Zhou, M. Y.; Yi P.; Wu, J and Cheng, M.L. (2009): Protective effect of blueberry against acute hepatic injury in rats. Zhongguo Ganzang Zazhi . 14(8): 33-35
- 71- Willett, W.C.; Sacks Fand Trichopoulou, A. (1995): Mediterranean diet pyramid: a cultural model for healthy eating. Am. J. Clin. Nutr., 61: 1402S-1406S.
- 72- Wink, M. (2003): Evolution of secondary metabolites from an ecological and molecular phylogenetic perspective. Phytochem.6(4):3 19-37.
- 73- World Health Organization (WHO) statistics the Institute for Health Metrics and Evaluation (IHME) 2013: GBD compare, Seattle, WA: IHME, University of Washington.
- 74- Xiong, J.S.; Branigan, D and Li M. (2009): Deciphering the MSG controversy. Int J ClinExp Med. 2(2):329-36

- 75- Xu, B.J and Chang, K.C. (2007): A comparative study on phenolic profiles and antioxidant activities of legumes as affected by extraction solvents. J Food Sci. 72:159-166.
- 76- Yilmaz, A. L.; Karaman, A. J.; Vardi, N.A and Cetin, E. E (2013): Effects of organic apricot on liver regeneration after partial hepatectomy in rats. Department of Pharmacology, Inonu University. 45(6):2455-60.
- 77- Zhu, S and Gouaux, E. (2017): Structure and symmetry inform gating principles of ionotropic glutamate receptors. Neuropharmacology. 11(2):11-5.

التأثيرات الوقائية المحتملة لبعض الفواكه المجففة ضد الإجهاد التأكسدي الناجم عن جلوتامات أحادية الصوديوم (MSG) في الفئران

إيريني ولسن نجيب وهالة راشد عطايا

تغذية وعلوم الاطعمه - قسم الاقتصاد المنزلي- كلية التربية النوعية- جامعة عين شمس

الملخص العربي

أجريت هذه الدراسة لتحديد تأثير المشمش المجفف والتين المجفف والتوت المجفف ضد الإجهاد التأكسدي في الفئران. تم تقسيم 54 من فئران التجارب البيضاء الذكور البالغة يتراوح وزنها 150-160 جرام إلى مجموعتين رئيسيتين. المجموعة الأولى كانت المجموعة التجريبية السالبة (9 فئران ، المجموعة الثانية (45) فأر وتم تقسيمهم إلى 5 مجموعات فرعية متساوية، المجموعة الفرعية الأولى كانت المجموعة التجريبية الموجبه وتغذت علي الوجبه الاساسيه، بينما المجموعة الفرعية الثانية تغذت علي الوجبه الاساسيه بجانب (15%) تين مجفف و (15%) مشمش مجفف، المجموعة الفرعية الثالثة تغذت علي الوجبه الاساسيه بجانب (15%) تين مجفف و المجموعة الفرعية الرابعة تغذت علي الوجبه الاساسيه بجانب (15%) توت مجفف واخيراً المجموعة الخامسة تغذت علي الوجبه الاساسيه بجانب 15% لكلاً من (مشمش ، تين ، توت) مجففين، وتم إعطاء جميع المجموعات الفرعية جلوتامات أحادية الصوديوم (MSG) بنسبة 7% من الوجبه الاساسيه بواقع 4.9 جم / كجم من وزن الجسم للفئران يومياً لمدة شهر. أفضل نتيجة سجلت من قبل المجموعة التي تم تغذيتها علي الوجبه الاساسيه المحتوية علي (15%) من الفواكه المجففة المشمش والتين والتوت وأدي الي حدوث تحسناً في كلاً من المأخوذ اليومي والوزن المكتسب ونسبه كفاءه الغذاء وكذلك في إنزيمات الكبد وظائف الكلى و انزيم الاكسده MDA مقارنة بالمجموعات الفرعية الاخرى . أكدت نتائج الفحص الهستوباثولوجي نفس النتائج السابقة. توصي هذه النتائج بزيادة استهلاك الفواكه المجففة لكلاً من المشمش والتين والتوت في خفض خطر الاجهاد التأكسدي وأضراره. وكذلك الحاجة لبرامج التثقيف الغذائي لتوضيح أهميتهم في تقليل التأثير غير المرغوب فيه للجلوتامات أحادية الصوديوم.

الكلمات المفتاحية:

أحادى جلوتامات الصوديوم ، أجهاد تأكسدي، مشمش مجفف ، تين مجفف، توت مجفف